

A new combination therapy for scalp alopecia areata: a study of high negative pressure microdermabrasion + intralesional steroids

Abstract

Alopecia Areata (AA) is an auto immune disorder of hair bearing areas of the skin. The incidence of alopecia areata has been increasing over the last few years. This condition affects 0.1-0.2% of humans, occurring in both men and women. AA occurs in people who are apparently healthy and have no existing skin disorders. Different regimens are already in practice including local irritants such as capsicum lotion, topical steroids, and oral immuno suppressants, oral and injectable steroids. Hair regrowth results are variable, either uniform or like bushes, and recurrence is very common.

This paper aims to present a study of a relatively new combination procedure to treat AA. In our study we combined high negative pressure microdermabrasion (MD) with intra lesional steroid (ILST) injection. We compared the results of this combination with ILST alone also.

Keywords: alopecia areata, microdermabrasion, intralesional steroid, aluminium oxide crystals, exclamation marks

Volume 2 Issue 1 - 2018

Sheikh MI

Consultant dermatologist, Alhamd Skin Clinic, Pakistan

Correspondence: M Iftikhar Sheikh, Consultant dermatologist, Alhamd Skin Clinic, Tel +923009423032, Pakistan, Email iftikhar96@hotmail.com

Received: December 08, 2017 | **Published:** February 08, 2018

Abbreviations: MD, microdermabrasion; ILST, intra lesional steroid

Introduction

In AA the affected skin usually appears like smooth bald skin spots (spot baldness) which may show broken hair known as short stubs (exclamation marks).³ In this combination therapy, during each session MD was carried out followed by ILST.

Microdermabrasion can result in

- Very effective and controlled irritation of scalp (contact immunotherapy).
- Cleansing of plugged follicular canals.
- Assistance in uniform distribution of injected ILST.
- Improves blood flow (indirectly helping immunotherapy).

The ILST: This provides immunosuppression⁴⁻⁶ and is given in a dose according to the area of scalp involved.

Materials and methods

This combination therapy of MD followed by ILST constituted one session. Each patient had 6 sessions every 15-20 days. MD was performed with aluminium oxide crystals with a specially designed hand piece (made in Pakistan) that had a wide hole at its tip, suctioning almost 1cm square chunk of skin and shot a crystal jet in a fan like movement abrading a fine layer of skin. The wide bore tip of hand piece of MD machine moved linearly over AA area of scalp at slow speed with high negative pressure (Figure 1).

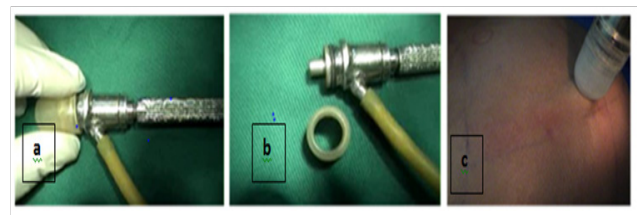


Figure 1 The specially designed hand piece for MD, with wide hole at tip, suctioning almost 1cm square chunk of skin due to high negative pressure and abrading fine layer of skin by shooting crystal and producing very affective skin irritation.
(A) Hand Piece.
(B) Wide Hole Tip.
(C) High Negative Pressure Suctioning Skin While Hand Piece Moving Linearly.

This was followed by injection of 0.02cc (0.8mg) of undiluted ILST to an approximately 2 inch square area or AA on the scalp with 30G needle (Figure 2).

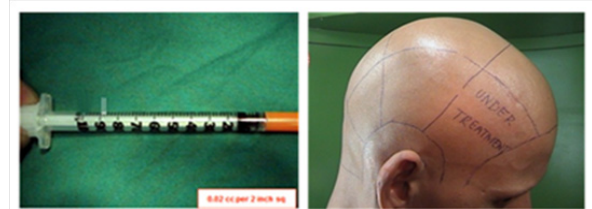

Figure 2 The syringe shows the amount of undiluted ILST between 2 adjacent white arrows, and the scalp shows the area of AA divided into 2" square boxes. 0.02cc (0.8mg) of ILST is given into the center of each square.

Inclusion criteria

- Willing patient only and otherwise healthy.
- Non scarring alopecia.
- No concomitant infection.

Exclusion criteria

- Patients with unhealthy skin of the scalp due to eczema, fungus or other infections.
- Scarring alopecia.
- Pregnancy.
- Diabetes.

Pre-procedure

- Photos of all patients were taken at the start and during treatment sessions for reference, to assess the progress, to record improvement and to evaluate the result of this treatment.
- All patients not gave any other medicine.
- All patients given detailed information about MD, ILST and consent taken.

So a study of this combination was done in 70 patients, in both sexes, in different age groups from January 2013 to January 2016. A comparison was also done with ILST alone (Table 1).

Table 1 This table shows the study protocol

Study period proposed 3 year	From January 2013 to January 2016, follow up continued to date
Total number of patient 70	50 patients treated with combination of MD+ILST
Males 45 female 25	20 patients treated with ILST alone
Age 5-50 years	Mean age 20 years
Treatment duration 3-5 months	Mean treatment duration 4 months
Each patient had six sessions every 15 to 20 days.	

Results and discussion

With our combination treatment (MD+ILST), all patients had remarkable improvement. Hair regrowth was usually obvious after third or fourth session. There was usually enough growth in 5-6 sessions. The regrowth of hair was fast full and very uniform (Figure 3).

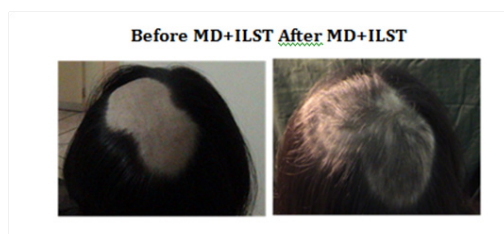


Figure 3 The combination of MD+ILST gives uniform and full growth (after 4th Session).
With ILST alone the growth was slower, less uniform, like bushes, unevenly distributed, with areas of no grow.

With ILST alone the growth was slower, less uniform, like bushes, unevenly distributed, with areas of no grow (Figure 4) (Figure 5).

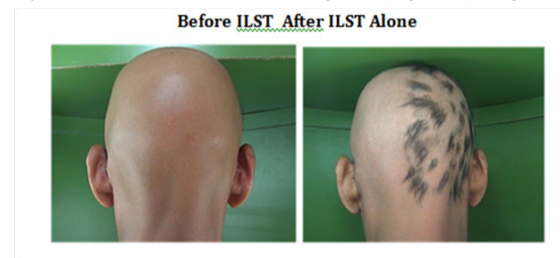

Figure 4 The ILST alone without MD gives uneven hair regrowth like bushes.

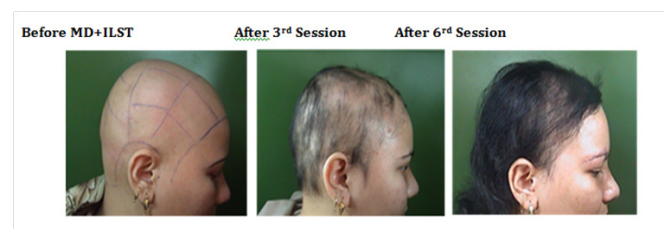

Figure 5 The combination of MD+ILST.

We proposed result criteria as following

- Complete response (80-100%) All patches full, uniform re growth and no recurrence before 6 months.
- Partial response (50-80%) Most patches had enough growth, but the growth was not full, less uniform and there was recurrence in less than 6 months.
- No response (<50%) Hair growth was not optimum and new lesions continued.

Our results of MD + ILST for the 50 patients were

- Complete response in 35 patients (70%).
- Partial response in 10 patients (20%).
- No response in 5 patients (10%).

Table 2 Recurrence rate after stopping treatment

Recurrence for all 50 patients (MD+ILST)			
After 4-6months	After 6-12months	After 12-24months	
5 Patients (10%)	9 Patients (18%)	12	Patients (24%)

Conclusion

Our results indicate that MD+ILST are safe and very effective treatment for AA. MD produces controlled irritation of bald skin, suctioned follicular plugs, improved blood flow and enabled uniform distribution of ILST. The ILST provides immunosuppression. The recurrence rate after stopping treatment is from 10-24% from 6 months to 24 months.

Acknowledgements

Special thanks to Shehla Bajwa, Rabia Nisar and Zainab Nisar for their untiring efforts in making this study.

Conflict of interest

There is no conflict of interest and no financial assistance.

References

1. Brzezińska-Wcisło L, Bergler-Czop B, Wcisło-Dziadecka D, et al. New aspects of the treatment of alopecia areata. *Postepy Dermatol Alergol.* 2014;31(4):262–265.
2. Burgdorf WHC, Plewig G, Wolff HH, et al. *Braun-Falco's Dermatology.* Lublin, Europe: Springer; 2010. p. 1053–1083.
3. Brzezińska-Wcisło L, Lis A, Kamińska G, et al. Physiology and pathology of growth and loss of human scalp hair. *Postep Derm Alergol.* 2003;20:260–266.
4. Łuczak M, Łuczak T, Cieścińska C, et al. General treatment of alopecia areata. *Przeegl Dermatol.* 2013;100:53–58.
5. Brzezińska-Wcisło L, Wcisło-Dziadecka D, Meszyńska E, New perspectives on the pathogenesis and treatment of hair disorders. *Post Nauk Med.* 2012;10:800–805.
6. Miteva M, Tosti A. Treatment options for alopecia: an update looking to the future. *Expert Opin Pharmacother.* 2012;13(9):1271–1281.